

Rare Case of Intramuscular Hemangioma in the Omohyoid Muscle

Muneesh Sharma and Ashla Moss*

Department of Imaging, Doctors Hospital Nassau, Bahamas

*Corresponding author: Moss A, Department of Imaging, Doctors Hospital Nassau, Bahamas, E-mail: amoss90@hotmail.com

Received: October 16, 2017; Revised: October 27, 2017; Published: November 03, 2017

Copyright: © 2017 Moss A, et al. This is an open-access article distributed under the terms of the Creative Commons Attribution License, which permits unrestricted use, distribution, and reproduction in any medium, provided the original author and source are credited. The article has been previewed and authenticated by the Authors before sending the publication for print. The Journal, Editor and the Editorial Board are not entitled or liable to either justify or responsible for inaccurate and misleading data if any. It is the sole responsibility of the Author concerned.

Citation: Sharma M, Moss A. Rare Case of Intramuscular Hemangioma in the Omohyoid Muscle. *Int J Gen Med Surg* 2017; 1: 114.

Abstract

Intramuscular hemangiomas are rare benign vascular tumors which account for less than 1% of all hemangiomas (though their true incidence and prevalence are difficult to calculate due to common misdiagnosis secondary to its diverse clinical presentation, deep location and rarity). They predominantly affect the trunk and extremities but, in rare occasions, can be found in the head and neck region mostly involving the masseter and trapezius muscles. An intramuscular hemangioma in the omohyoid muscle is considered an extremely rare finding. This case report is that of a 26 year old Afro-Caribbean male who presented with a painless mass on the right anterior aspect of the neck which was investigated using ultrasound and MRI and later confirmed as an intramuscular hemangioma in the omohyoid muscle by biopsy and histopathology.

Keywords: Hemangioma; Intramuscular; Omohyoid; Soft tissue mass; Rare; Benign

Introduction

Hemangiomas are classified as benign tumors which are comprised of an abnormal proliferation of blood vessels and make up approximately 7% of all benign soft tissue tumors [1,2,3]. They are generally found affecting the mucosa and cutaneous regions but, less commonly, can be found in the muscles. Intramuscular hemangiomas are an uncommon variation of the hemangioma and have been found to represent 0.8% of all hemangiomas [2,4,5]. Approximately 14% of all intramuscular hemangiomas are found in the region of the head and neck (most commonly affecting the masseter muscle followed by the trapezius muscle) [2,6,7]. A comprehensive

PubMed and Radiology database search did not reveal any previously documented intramuscular hemangioma in the omohyoid muscle.

Case Report

History

A 26 year old afro-caribbean male with no known pertinent medical history presented to the imaging department complaining of a painless mass of long duration in the right supraclavicular region which had marginally increased in size over a period of 3 months. Patient's primary concern was aesthetics and desired further evaluation and treatment of the aforementioned mass.

On physical examination

A firm, non-tender, immobile, non-pulsatile, non-circumscribed, mass located in the right supraclavicular region with extension along the anterior aspect of the neck was noted (**Figure 1 and Figure 2**).

No discoloration of the overlying skin, no scars noted, normal range of motion of neck and shoulder. No neurological deficits (sensory or motor).

Investigations

Ultrasound & MRI of the neck were performed, representative images are shown below with the description of the findings.

Ultrasound Study

High frequency linear probe USG evaluation was done (**Figure 3A, Figure 3B and Figure 3C**) with color Doppler interrogation which revealed that both bellies of the right omohyoid muscle were bulky.

Taking into consideration the physical findings and ultrasound imaging results, a provisional diagnosis of an intramuscular hemangioma was made with unlikely differential considerations of an infiltrating neurofibroma/MPNST (Malignant Peripheral Nerve Sheath Tumor), lipoma, cystic hygroma, pleomorphic adenoma or rhabdomyosarcoma. An MRI was then performed to confirm diagnosis and rule out any malignant process.

MRI Findings

A 1.5 T MRI of the neck with a wide FOV to also cover the supraclavicular fossa was performed (**Figure 4A, Figure 4B and Figure 4C**). MRI image findings further supported the provisional diagnosis of an intramuscular hemangioma.

Ultrasound Guided Biopsy

Owing to the rarity of the above provisional diagnosis and on insistence of the patient (even after being informed of the risks involved) a biopsy was carried out using a 16 G Core biopsy needle targeting the mid aspect of the superior belly of the right omohyoid muscle

from a medial to lateral approach, under local anesthesia and direct continuous sonographic control (**Figure 3**). The needle was fired laterally into the bulk of the muscle after anchoring into it, pointing away from the major artery and vein and laryngeal apparatus.

Samples collected were placed in a formalin container and sent for histopathology. Local compression was applied to biopsy site and ice pack was placed.

Post-procedural ultrasound was performed to evaluate biopsy site; no overt post-procedural complication was observed.

Histopathology

Histopathology results were received within 1 week.

Biopsy samples collected were described on gross examination as grey white soft tissue fragments aggregating.

Microscopic evaluation of biopsy tissue samples (**Figure 4**) yielded a final histopathological diagnosis: skeletal muscle (omohyoid) with changes consistent with intramuscular hemangioma.

Discussion

Hemangiomas are benign tumors which represent approximately 7 % of all benign soft tissue tumors [1,2,3]. They are predominantly found in the skin and subcutaneous tissues primarily affecting the trunk and extremities followed by the head and neck region (which accounts for approximately 13.5 to 21%) and rarely involve the oro-facial muscles (less than 1%) [6,8]. Intramuscular hemangiomas are less common and are said to represent less than 1 % of all hemangiomas (approximately 0.8%) [8]. Intramuscular hemangiomas generally occur within the first three decades of life and have shown an equal sex distribution (although involvement of the masseter has shown male predominance) [4,5,9].

Various theories were proposed with regards to etiopathogenesis. The theory of congenital etiology was entertained and supported by its typical presentation within the first three decades of life. Trauma is also a predominant theory with regards to origin. A possible

hormonal role in the growth process of these masses was speculated due to sudden increase in size in some patients taking oral contraceptive pills (but no specific data was available to substantiate said theory) [4,5].

Approximately 14% of the intramuscular hemangiomas are found in the region of the head and neck as stated above affecting the masseter (36%), followed by the trapezius (24%) [2,6,7]. Clinically they typically present as a painless mass and rarely present as musculoskeletal pain (though chronic musculoskeletal pain may occur). Other symptoms include localized pulsations and change in color of skin located over mass.

Diagnosis of an intramuscular hemangioma begins clinically upon physical examination (palpation and inspection) of a soft tissue mass in a young patient and should always be considered as a possible differential diagnosis. Upon obtaining patient history and physical examination, provisional diagnosis can be confirmed with the use of imaging. Due to the diversity in possible locations and often unfamiliar presentation of intramuscular hemangiomas, sonography, magnetic resonance imaging (MRI) and sometimes angiography may be required for accurate diagnosis.

Due to its multiplanar capabilities and ability to distinguish unaffected muscle from this pathology, MRI has proven superior to Computed Tomography in the evaluation of an intramuscular hemangioma. Characteristically, the increased water content within the blood vessels of the lesion appears brighter on T2 STIR than T1 weighted images [8]. MRI is also useful in determining the extent, exact location and parameters of the lesion and is now routinely used to characterize/localize intramuscular hemangiomas. Angiography has also been performed for peripheral hemangiomas to evaluate its vascularity and vascular supply [1]. Though MRI is a useful tool, multiple imaging modalities should be used in conjunction during the diagnostic process as each modality provides distinct imaging characteristics of the mass which aids in its diagnosis.

Usual treatment options include steroids, injection of sclerosing agents, radiation

therapy, and surgical excision [5,8]. Pre-operative embolization has also been performed in some cases to decrease intraoperative blood loss in large hemangiomas. The accepted optimal treatment of an intramuscular hemangioma is its total excision with surrounding normal muscle tissue but, treatment plan should be individualized; surgical excision is not required in all cases [8]. Accepted indications for surgery include; symptomatic but stable tumors, rapid growth, functional impairment, local skin necrosis, thrombocytopenia, cosmetic affectation and suspicion of malignancy [5]. Regional recurrences have been reported in approximately 18% of cases in which there was incomplete surgical resection of the mass [9]. True intramuscular hemangiomas have no malignant potential but management (surgical or non-surgical) should include interval assessments of the affected area [10].

In this case, physical examination revealed a firm, non-tender, immobile, non-pulsatile, non-circumscribed mass located in the right supraclavicular region, which when combined with ultrasound and MRI imaging studies, a provisional diagnosis of an intramuscular hemangioma of the omohyoid was made and later confirmed by histopathology. It took approximately 2 weeks to investigate and confirm diagnosis. Due to the extension, size, location and non-circumscribed borders of the hemangioma within the muscle, patient was referred to general surgery for surgical consult with plans of surgical excision.

Conclusion

This case demonstrates that though rare and variable in its presentation, an intramuscular hemangioma should be included in the differential diagnosis of any identified soft tissue mass (taking into consideration the history and other characteristics of the patient) and exhibits the fundamental role of imaging in the diagnostic process. Treatment should be individualized based on size, location, extent of lesion, clinical presentation, age, medical history, cosmetic considerations and desire of patient.

Conflict of Interest

The authors declare no conflict of interest.

Funding

Nil.

References

1. Kim DH, Hwang M, Kang YK, et al. Intramuscular hemangioma mimicking myofascial pain syndrome: A case report. J Korean Medical Sci 2007; 22: 580–582.
2. Chandrasekar LK, Sankarapandiyar S, Pulivadula MVS. Intramuscular haemangioma with diagnostic challenge: A cause for strange pain in the masseter muscle. Case Reports Dentistry 2014; 2014: 1-4
3. Bucci T, De Giulio F, Romano, A, et al. Cavernous haemangioma of the temporalis muscle: case report and review of the literature. Acta Otorhinolaryngologica Italica 2008; 28: 83–86.
4. Shpitzer T, Noyek AM, Witterick I, (1997). Noncutaneous cavernous hemangiomas of the head and neck. Am J Otolaryngol 1997; 18: 367-374.
5. Enzinger FM, Weiss SW. Benign tumors and tumorlike lesions of blood vessels. Soft tissue tumors, 3rd edn. Mosby, St Louis, 1995; 579–626
6. Nayak S, Shenoy A. Intra-muscular hemangioma: A review. J Orolfac Sci 2014; 6: 2-4.
7. Narayanan CD, Prakash P, Dhanasekaran CK. Intramuscular hemangioma of the masseter muscle: A case report. Cases J 2009; 2: 7459.
8. Hoehn JG, Farrow GM, Devine KD. Invasive hemangioma of the head and neck. Am J Surg 1970; 120: 495–498.
9. Kumar SLK, Kurien NM, Venugopal K, et al. Intramuscular hemangioma of the masseter muscle: A case report and review of literature. Int J Surgery Case Rep 2016; 26: 209–216.
10. Wolf GT, Daniel F, Krause CJ. Intramuscular hemangioma of the head and neck. Laryngoscope 1985; 95: 210.

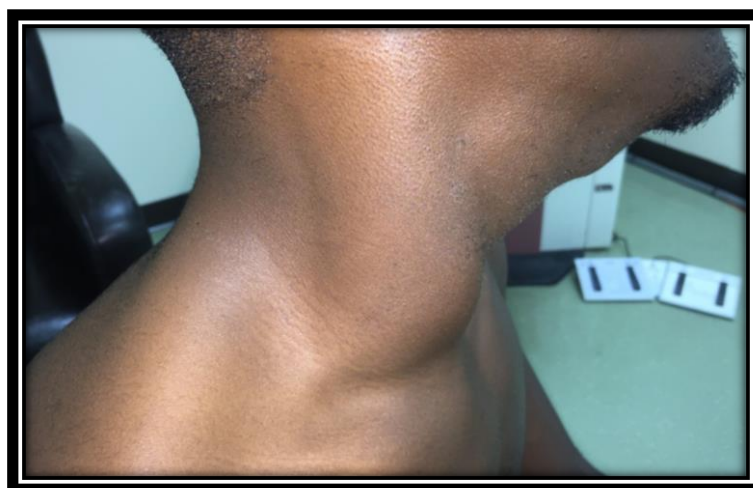

Figure 1: Shows lateral view of patient where asymmetric enlargement of the right lateral aspect of the neck is apparent

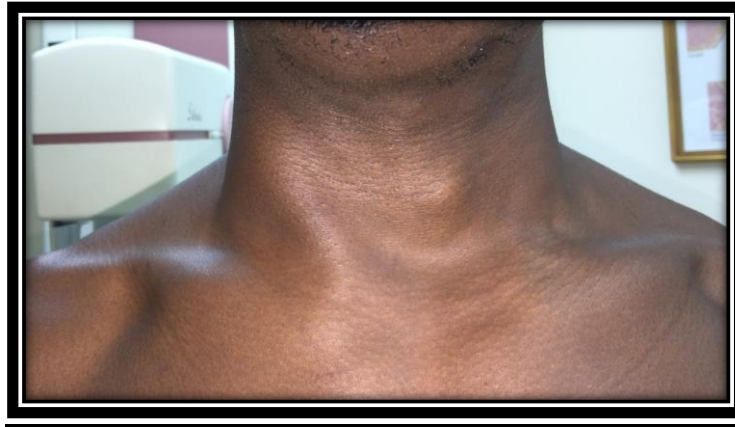

Figure 2: Shows AP view of patient with asymmetric enlargement of the right lateral aspect of the neck

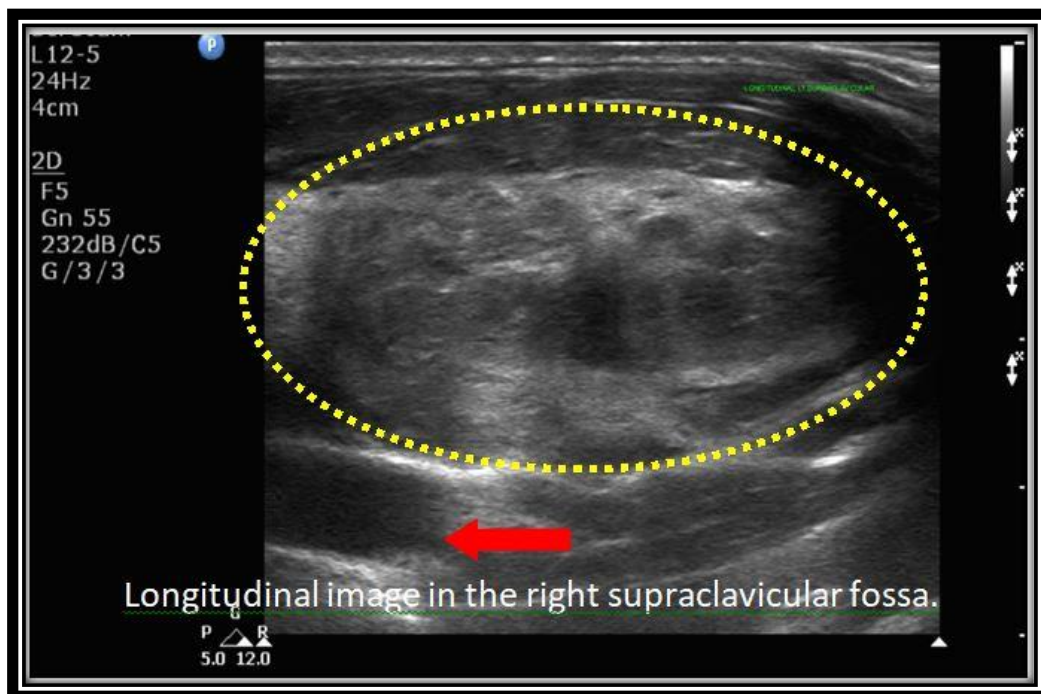


Figure 3 A: Shows the heterogeneously bulky but well circumscribed inferior belly of the omohyoid in the right supraclavicular fossa (within the dashed yellow circle). Right subclavian artery is marked by the red arrow. There is no cystic or calcific focus within the bulky muscle and fat planes around muscle are intact

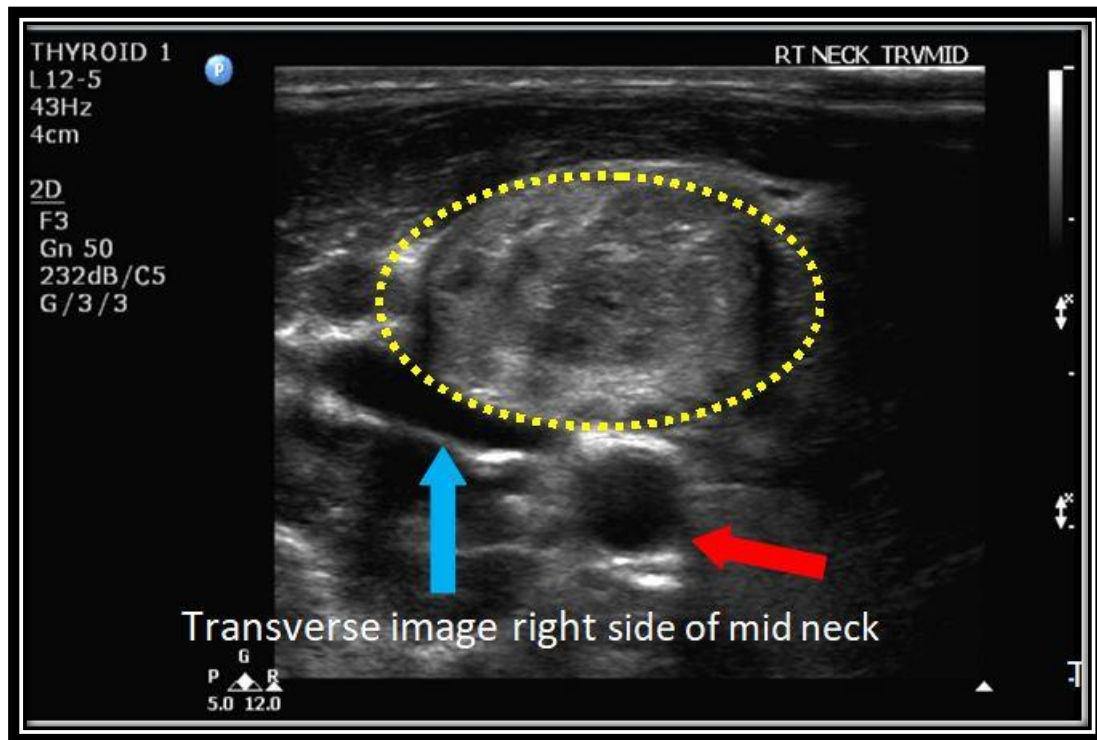


Figure 3 B: Shows the heterogeneously bulky but well circumscribed superior belly of the right omohyoid muscle (which is again outlined by the dashed yellow circle). The red arrow demonstrates the right common carotid artery and the right internal jugular vein is marked by the blue arrow

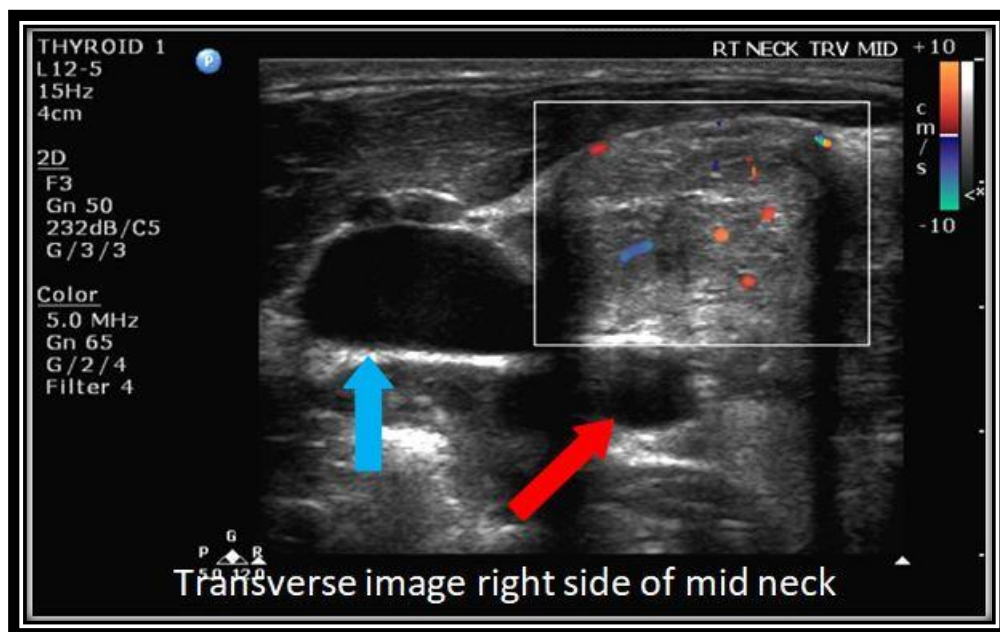


Figure 3 C: Was taken at about the same level as image B and shows increased flow on color Doppler as evident by the red and blue spots in the color box; Again the right internal jugular vein and right common carotid artery are marked by the blue and red arrows respectively

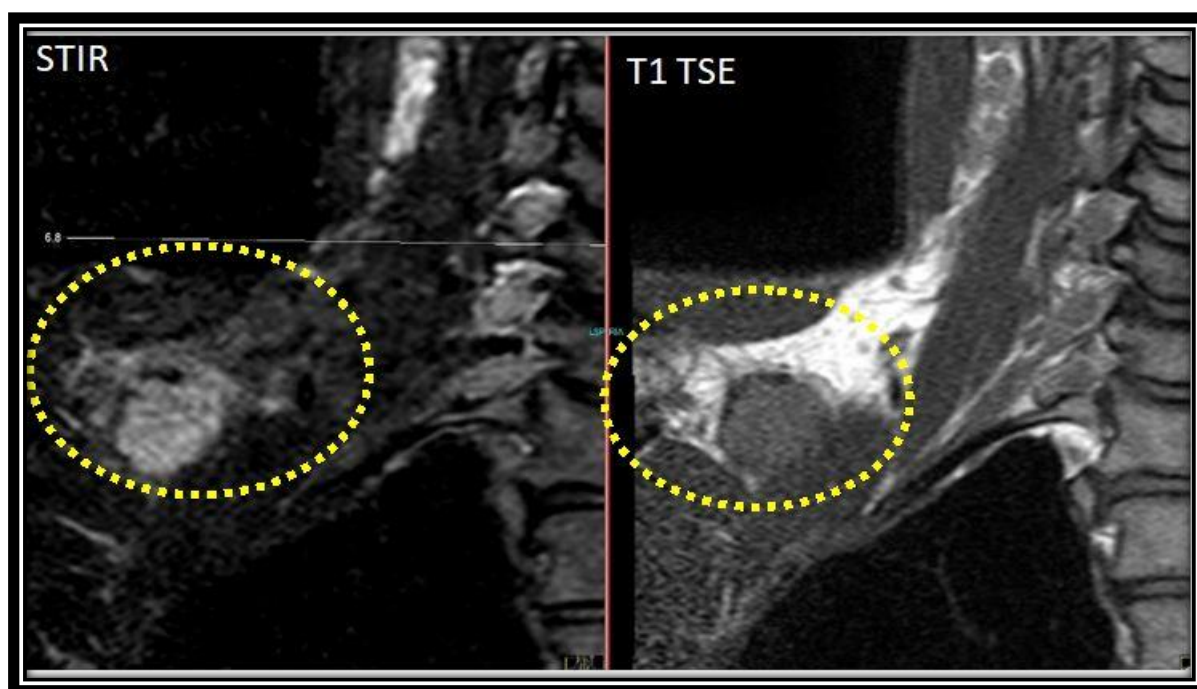


Figure 4 A: Coronal STIR (left) & Coronal T1 TSE (right)

They show that the inferior belly of the right omohyoid muscle (within the dotted yellow circle) is bulky with abnormal signal intensity - hyperintense on STIR, intermediate on T1. The tendinous component is seen as low signal bands at the upper aspect of the muscle

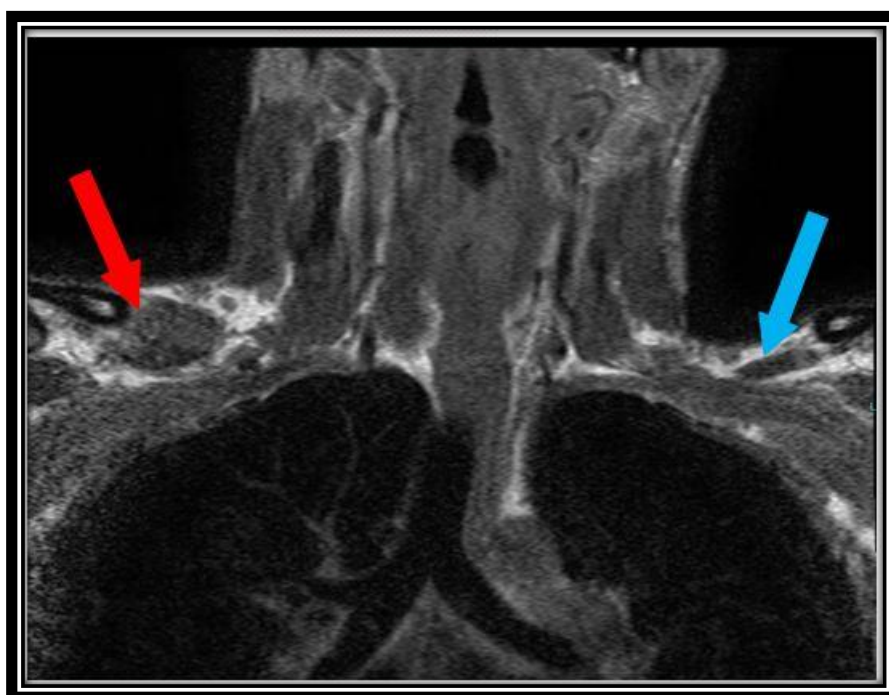


Figure 4 B: Coronal T1 TSE

A wide FOV image compares the inferior bellies of the bulky right (marked by the red arrow) and normal left (marked by the blue arrow) omohyoid muscle

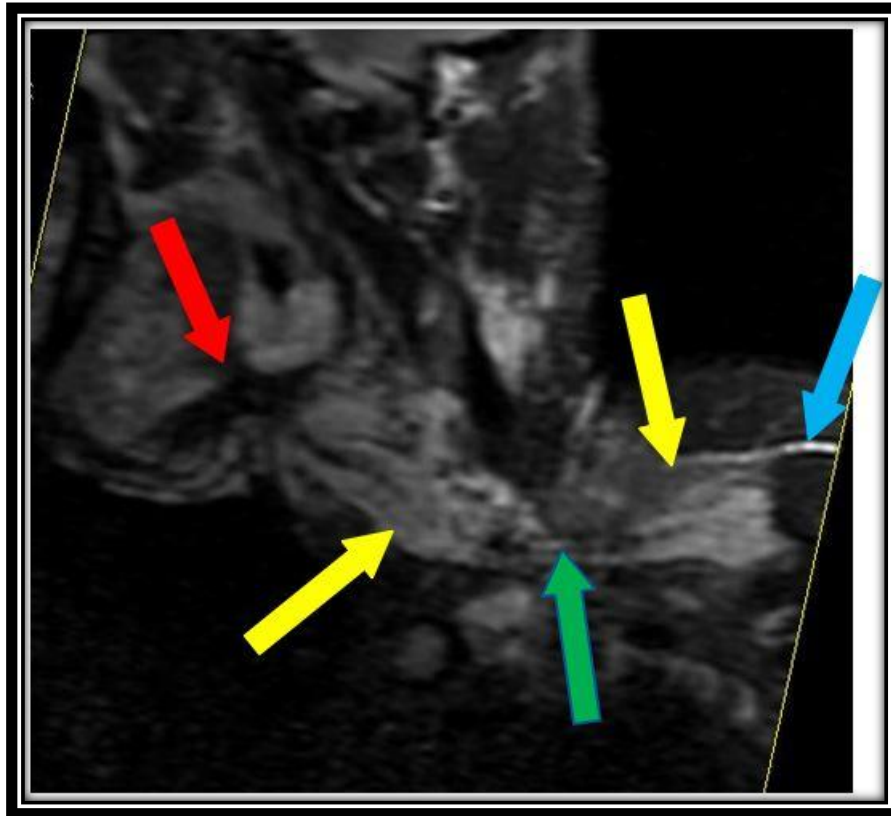


Figure 4 C: Oblique coronal STIR

An oblique coronal image was reconstructed from an MPR of the thin STIR stack and it shows the entire length of the right omohyoid (yellow arrows) with the narrow tendinous portion (green arrow) joining them. The red arrow points to the hyoid bone, the blue arrow points to the scapular spine

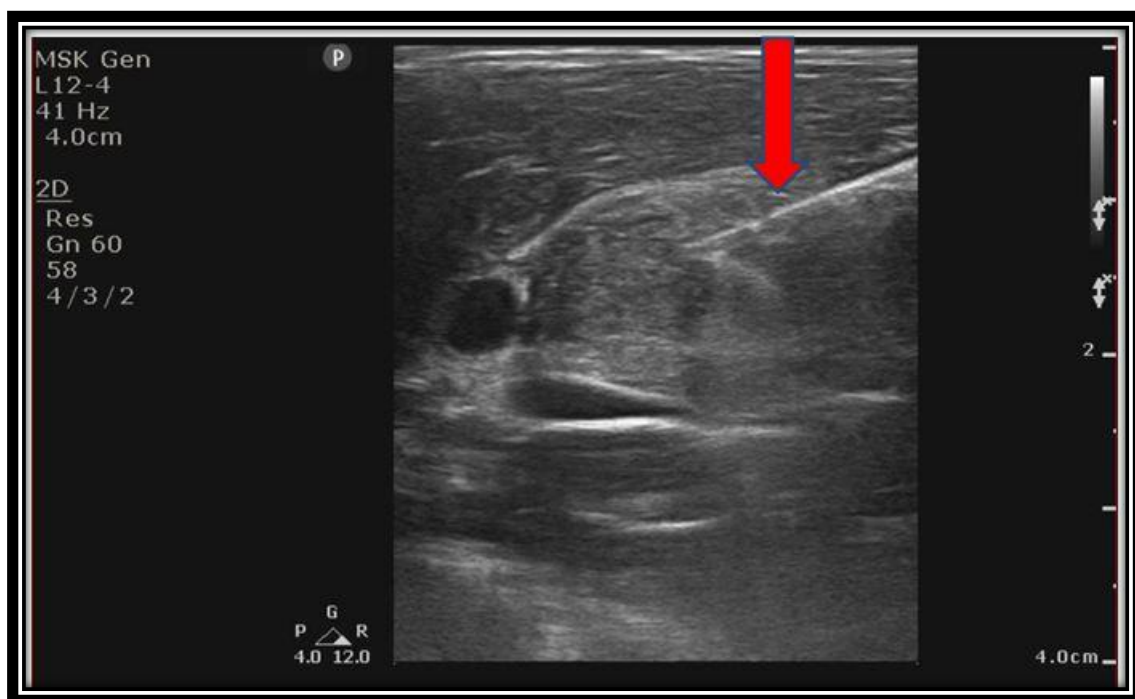


Figure 3: Image shows the biopsy needle, seen as straight white line marked by the red arrow, as it fires into the right omohyoid muscle

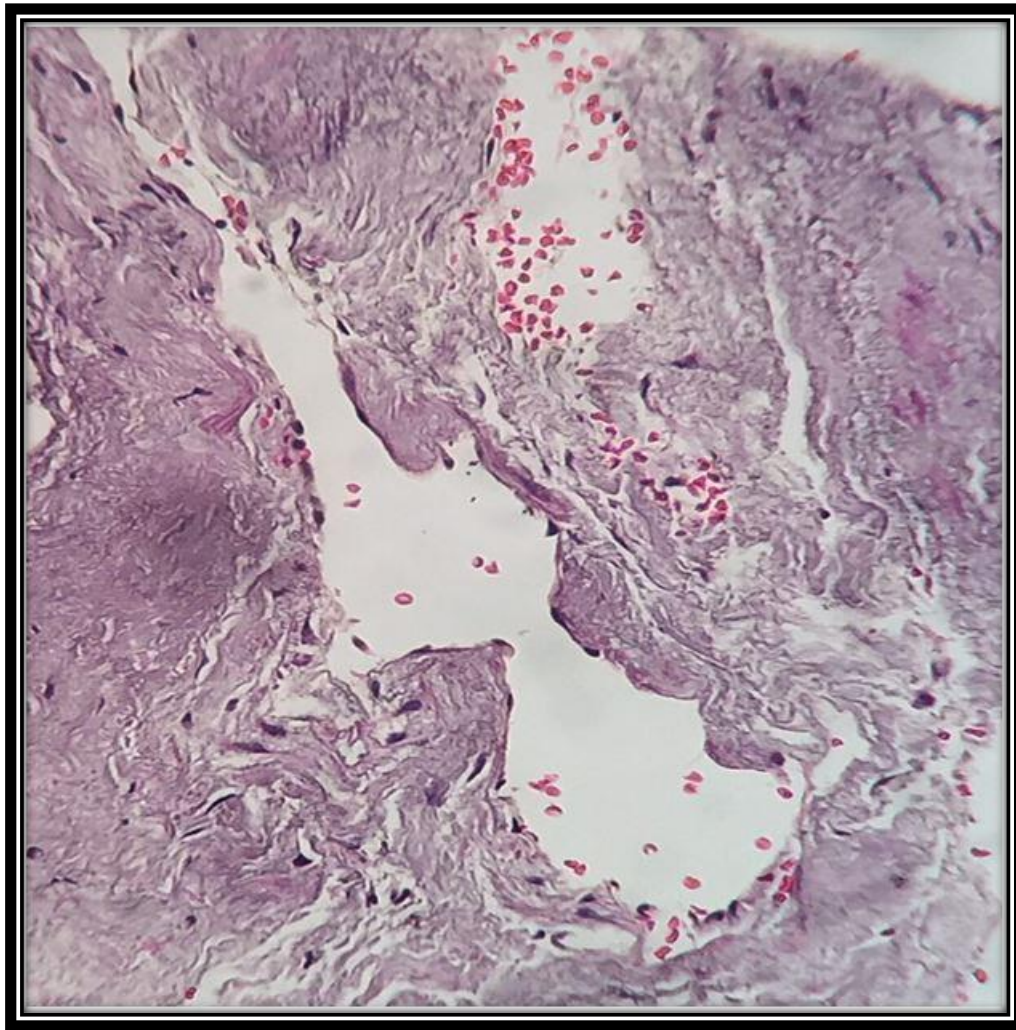


Figure 4: Histopathological view of the lesion. Collected samples showed fragmented portions of skeletal muscle with separate portions of tissue comprising of fibrovascular tissue with blood vessels of varying calibers and wall thickness lined by bland endothelial cells

This manuscript was peer-reviewed

Mode of Review: Single-blinded

Editor: Dr. Pawel Lizis

International Journal of General Medicine & Surgery is an open access, peer reviewed journal published by Edwiser International.

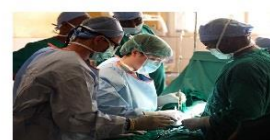Submit your valuable manuscript at-
editor.ijgms@edwiserinternational.com
submit.manuscript@edwiserinternational.com



**International Journal of
Pharmaceutics & Pharmacology**



**International Journal of
General Medicine & Surgery**



**International Journal of Trauma,
Acute Care & Surgery**



**International Journal of Advances
in Gynecology & Obstetrics**



**International Journal of Research
& Clinical Trials**

